



## PATIENT

Packer Smith

## SPECIES

Canine

## BREED

Terrier Mix

## SEX

FS

## AGE

12 y

## WEIGHT

17.5 lb

## INTERPRETED BY

Keith Blass, DVM, MS,  
DACVIM (Cardiology)

## IMAGING PERFORMED BY

Trish Turner, CVT

## HOSPITAL NAME

Straley VA

## REFERRING VET

Dr. Hubler

## INVOICE

## DATE

1/15/26

## PRESENTING CLINICAL SIGNS

Grade 4/6 murmur. Receiving zonisamide for seizures.

## ECHOCARDIOGRAPHIC FINDINGS

2D, M-mode, and Doppler study.

There is mild to moderate left atrial dilation. The mitral valve leaflets are thickened, and a moderate jet of mitral regurgitation is present. There is mild to moderate left ventricular internal dilation. Left ventricular systolic function is mildly hyperdynamic. The aorta and aortic valve appear normal. Right atrial and right ventricular dimensions are normal. The tricuspid valve appears normal, though trace tricuspid regurgitation is present. The pulmonary artery and pulmonic valve appear normal. No shunting lesions are visualized. No pericardial effusion or cardiac masses are seen.

LA - 35.2 mm  
LVIDd - 33.3 mm  
LVIDs - 18.5 mm  
FS - 44.4%  
RA - 17.3 mm

## ASSESSMENT/RECOMMENDATIONS

Degenerative mitral valve disease - stage B2

This examination demonstrates moderate regurgitation of blood across Packer's mitral valve resulting from degenerative valve disease. Secondary to her regurgitation, Packer has mild to moderate dilation of both her left atrium and left ventricle, though her left ventricular systolic function is well-preserved. Given this, Packer is at mildly to moderately increased risk for the development of clinical signs, such as coughing, exercise intolerance, syncope, and labored breathing, therefore, careful monitoring for these is recommended.

I recommend starting Packer on pimobendan (2.5 mg BID), as this medication should help to slow the progression of her mitral valve disease.

A recheck echocardiogram is recommended in 9 months. Thoracic radiographs are recommended if Packer experiences respiratory clinical signs.



#### PATIENT

Packer Smith

#### SPECIES

Canine

#### BREED

Terrier Mix

#### SEX

FS

#### AGE

12 y

#### WEIGHT

17.5 lb

#### INTERPRETED BY

Keith Blass, DVM, MS,  
DACVIM (Cardiology)

#### IMAGING PERFORMED BY

Trish Turner, CVT

#### HOSPITAL NAME

Straley VA

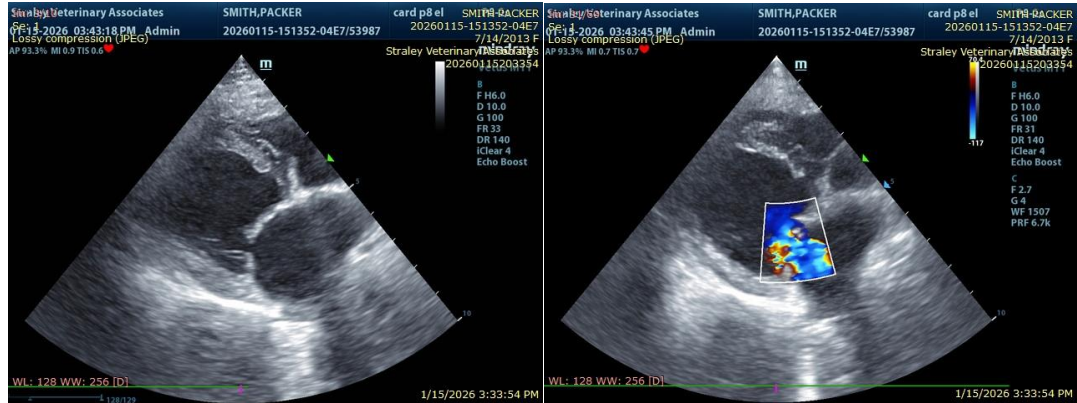
#### REFERRING VET

Dr. Hubler

#### INVOICE

#### DATE

1/15/26



The information and recommendations provided are based on the images presented by the referring veterinarian/sonographer. No evaluation can be communicated regarding pathology that was not visible in the image/video clips provided.

Thank you for this referral. If the clinical or image interpretation does not parallel your findings or if I can be of any further assistance please contact me.

Keith Blass, DVM, MS, DACVIM (Cardiology)

[info@SonoPath.com](mailto:info@SonoPath.com)